



Contents



GO Protocols – consistent results in all joints



CAIPRINHA SPACE – a winning combination



Learn from the experience of other MAGNETOM users

The MAGNETOM World is the community of Siemens Healthineers MR users worldwide, providing you with relevant clinical information. Here you will find application tips and protocols to optimize your daily work. Lectures and presentations from experts in the field will allow you to be exposed to new ideas and alternative clinical approaches.

Put the advantages of the MAGNETOM World to work for you!

siemens.com/magnetom-world

Editorial Comment

- 4 Jeffrey Sunshine, Case Western Reserve University and University Hospitals, Cleveland, OH, USA

Abdominal Imaging


- 11 Fast, Standardized, and Robust Imaging with BioMatrix and CS GRASP-VIBE
Johan Dehem, VZW Jan Yperman, Ypres, Belgium
- 19 How-I-do-it: MR Elastography¹ – Pearls and Pitfalls
Bradley Bolster, Siemens Healthineers, Malvern, PA, USA

Musculoskeletal Imaging

- 24 Improving Resolution, Productivity, and Diagnosis. SMS TSE and GO Protocols in an Optimized Clinical Workflow
Johan Dehem, VZW Jan Yperman, Ypres, Belgium
- 39 MR Imaging of Joint Replacements
Reto Sutter, Balgrist University Hospital, Zurich, Switzerland

Neurology

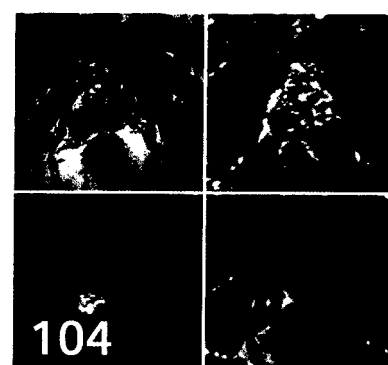
- 45 CAIPRINHA and SPACE – a Winning Combination
Michel Paret, et al., GIE IRMAS, Saint-Priest-en-Jarez, France



73 How-I-do-it: MR Spectroscopy



8 Why ultra-high-field MRI?



104 PI-RADS v2

- 52 **Clinical Utility of Amide Proton Transfer¹ Imaging in Patients with Brain Tumors**
Linda Knutsson et al., Lund University, Lund, Sweden
- 56 **ASL Perfusion Imaging: Clinical Experience in Patients with Cerebrovascular Steno-Occlusive Disease**
Toshibumi Kinoshita, et al., Research Institute for Brain and Blood Vessels-Akita, Akita, Japan
- 62 **Cerebral Blood Flow Measurements in Elderly Using Arterial Spin Labeling at 3T**
Peter J. Joris, et al., Maastricht University, Maastricht, The Netherlands
- 68 **Brain Perfusion Imaging in a Case of Thalamic Stroke: a Clinical Application of 3D Pseudo-Continuous ASL (PCASL)¹**
Fabrizio Esposito et al., University of Salerno, Baronissi (Salerno), Italy
- 73 **How-I-do-it: MR Spectroscopy in Neuroimaging – A Practical Guide to Integrate a Complex Technology into a Clinical Workflow**
Lawrence Ryner, et al., Health Sciences Center Winnipeg, Canada
- 83 **Why UHF MRI? A Personal Journey from Artifact to Anatomical History**
Christopher J. Wiggins, Scannexus, Maastricht, The Netherlands

Pediatric Imaging

- 87 **Fetal MR Imaging²: An Overview**
Guangbin Wang, et al., Shandong University, Shandong, China
- 99 **Small Structures Big Challenges: Fetal Cardiac Magnetic Resonance Imaging²**
Matthias Stuber, et al., University of Lausanne, CHUV, Lausanne, Switzerland

Men's Health

- 104 **Three Years of PI-RADS v2: Achievements, Open Questions and Future Perspectives**
Bernd Hamm, Charité University Hospital, Berlin, Germany

Image Gallery

- 107 **1.5T MAGNETOM Altea and 3T MAGNETOM Lumina³ – Confidence to Deliver**

Meet Siemens Healthineers

- 111 **Introducing Ning Jin, Chicago, USA and Christoph Forman, Erlangen, Germany**