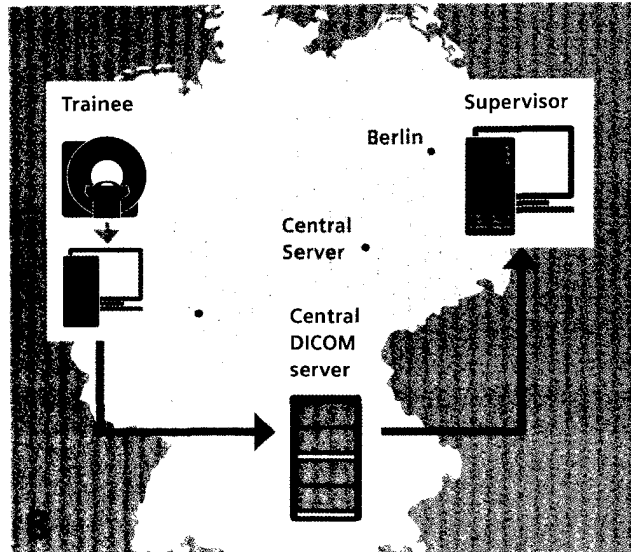



Content



CMR Teaching Network



Non-contrast tissue characterization with T1 and T2 mapping



Don't miss the wealth of clinical information at www.siemens.com/magnetom-world

Learn from the experience of other MAGNETOM users

The MAGNETOM World is the community of Siemens MR users worldwide, providing you with relevant clinical information. Here you will find application tips and protocols to optimize your daily work. Lectures and presentations from experts in the field will allow you to be exposed to new ideas and alternative clinical approaches.

Put the advantages of the MAGNETOM World to work for you!


www.siemens.com/magnetom-world

- 2 The Future of Cardiovascular Magnetic Resonance
Eike Nagel, DZHK Centre for Cardiovascular Imaging, University Hospital Frankfurt/Main, Germany
- 8 Cardiovascular Magnetic Resonance Teaching Network. Requirements for Simplified Distribution and Sustained Quality
Jeanette Schulz-Menger, et al., Charité Medical Faculty and HELIOS Clinic Berlin-Buch, Germany
- 18 Case Report: Acute Myocardial Syndrome in a 37-Year-Old Patient with Severe Renal Impairment
Anna S. Herrey, et al., The Barts Heart Centre, London, UK
- 20 Case Report: Detection of Myocardial Changes in a Patient Undergoing Chemotherapy
Steve W. Leung, et al., University of Kentucky Medical Center, Lexington, KY, USA
- 22 Case Report: Myocardial Fibrosis in a Non-Ischemic Cardiomyopathy
Jeremy D. Collins, et al., Feinberg School of Medicine, Northwestern University, Chicago, IL, USA
- 26 Case Report: Clinical Usability of MyoMaps in Myocardial Infarction
Masashi Nakamura, Saiseikai Matsuyama Hospital, Matsuyama, Ehime, Japan



22

Myocardial Fibrosis
in a Non-Ischemic
Cardiomyopathy



30

QISS lower extremity MRA



48

Delayed Enhanced Cardiac MRI in the
Assessment of Cardiomyopathies

-
- 30** Quiescent Interval Single-Shot (QISS) Lower Extremity MRA for the Diagnosis of Peripheral Artery Disease: Case Presentations
Akos Varga-Szemes, et al., Medical University of South Carolina, Charleston, SC, USA
- 36** Case Report: QISS MRA at 3T
Anna-Maria Lydon, et al., University of Auckland, New Zealand
- 38** Cardiac Diffusion Tensor MRI Using SMS Acquisition with a Blipped-CAIPIRINHA Readout
Choukri Mekkaoui, et al., Massachusetts General Hospital, Harvard Medical School, Boston, MA, USA
- 41** Self-Navigated Free-Breathing High-Resolution 3D Cardiac Imaging: A New Sequence for Assessing Cardiovascular Congenital Malformations
Juerg Schwitter, et al., University Hospital of Lausanne (CHUV), Lausanne, Switzerland
- 48** Utility of Delayed Enhanced Cardiac MRI in the Assessment of Cardiomyopathies
Dipan J. Shah, et al., Houston Methodist Hospital, Houston, TX, USA
- 52** **How-I-do-it:** Reconstructing synthetic MOLLI and PSIR images
Magalie Viallon, et al., Université de Lyon, France
- 57** *syngo*.MR Cardiac 4D Ventricular Function
Bernd J. Wintersperger, et al., University Health Network, University of Toronto, Canada